

Your Practice Online

P R E S E N T S

Femoroacetabular Impingement

Multimedia Health Education

Disclaimer

This movie is an educational resource only and should not be used to manage Orthopaedic health. All decisions about the management of Femoroacetabular impingement must be made in conjunction with your Physician or a licensed healthcare provider.

Australia

Dr. Prem Lobo
G.P.O Box No.635
SYDNEY NSW- 2001

Phone: 1 800 883 260
Fax: +61 2 9475 1036
Email: info@yourpracticeonline.com.au

USA

Holly Edmonds RN, CLNC
1006 Triple Crown Drive
Indian Trail, NC 28079

Toll Free: 1 877 388 8569 (Toll Free)
Fax: 1 718 785 9593
Email: info@yourpracticeonline.net

New Zealand

Greg Eden
P O Box 17 340 Greenlane
Auckland 1130

Phone: +09 974 9839
Fax: +64 9 634 6282
Email: info@yourpracticeonline.co.nz

WWW.YOURPRACTICEONLINE.NET

Your Practice Online

MULTIMEDIA HEALTH EDUCATION MANUAL

TABLE OF CONTENTS

SECTION	CONTENT
1 . Normal Hip Anatomy	
	a. Introduction
	b. Normal Hip Anatomy
2 . Femoroacetabular Impingement	
	a. What is FAI?
	b. Symptoms
	c. Risk Factors
	d. Diagnosis
	e. Conservative Treatment
3 . Surgical Procedure	
	a. Introduction
	b. Surgical Treatment
	c. Post Operative Care
	d. Risks and Complications

INTRODUCTION

Femoroacetabular is the term to describe the location where the femur (thigh bone) and the acetabulum (hip socket) come together. Impingement is a term that refers to pinching. Therefore, a diagnosis of femoroacetabular impingement indicates a pinching or pain in the hip where the femur meets the hip socket.

Introduction

In a normal hip, the head of the femur moves smoothly within the hip socket enabling movement without pain. With femoroacetabular impingement or FAI, the femur pinches against the cartilage in the hip socket impeding smooth movement and causing pain. In order to learn more about FAI, it helps to understand the normal anatomy of the hip.

Normal Hip Anatomy

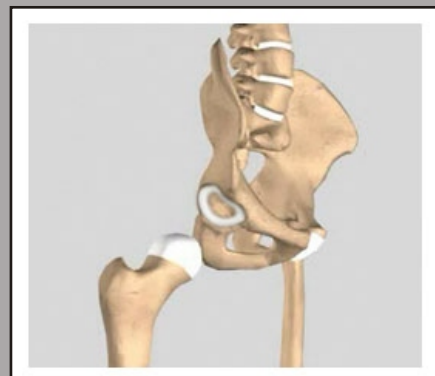The thigh bone, femur, and the pelvis, acetabulum, join to form the hip joint. The hip joint is a “ball and socket” joint. The “ball” is the head of the femur, or thigh bone, and the “socket” is the cup shaped acetabulum. The joint surface is covered by a smooth articular surface that allows pain free movement in the joint.

The cartilage cushions the joint and allows the bones to move on each other with smooth movements. This cartilage does not show up on X-ray, therefore you can see a “joint space” between the femoral head and acetabular socket. The labrum is a ring of dense fibrocartilage tissue lining the outer rim of the hip socket giving depth and stability to the hip joint.

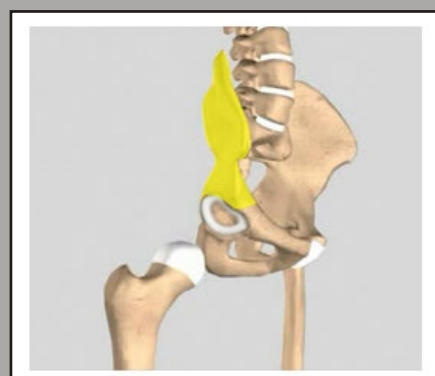- Ilium
- Ischium
- Pubis
- Acetabulum
- Femur
- Cartilage
- Labrum

Ilium

(Refer fig. 2)



(Fig. 1)



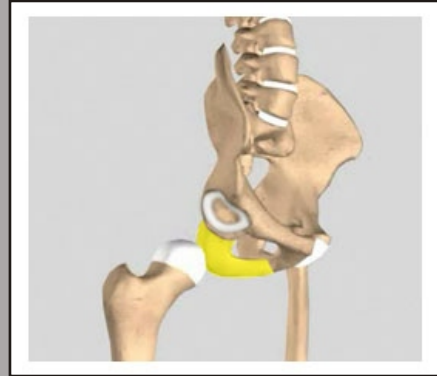
(Fig. 2)

Unit 1:

Normal Hip Anatomy

Ischium

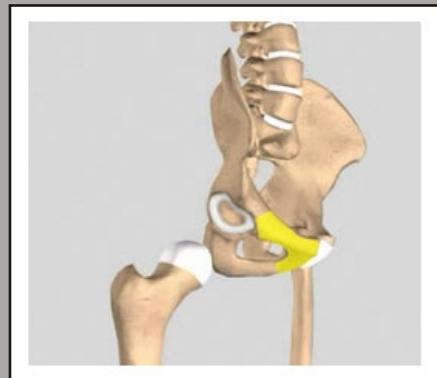(Refer fig. 3)



(Fig. 3)

Pubis

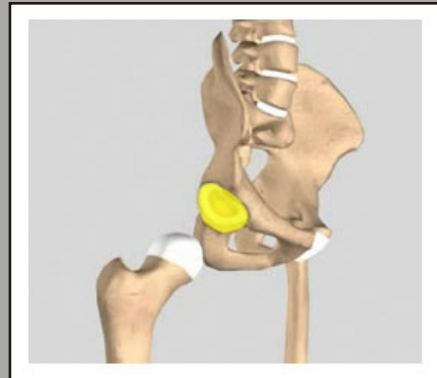
(Refer fig. 4)



(Fig. 4)

Acetabulum

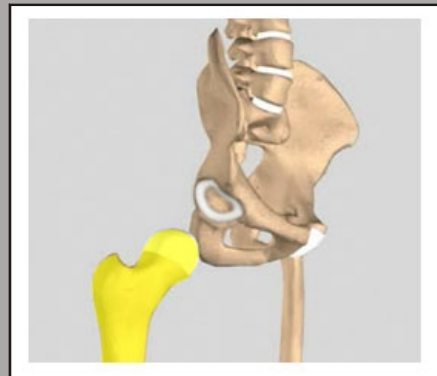(Refer fig. 5)



(Fig. 5)

Femur

(Refer fig. 6)



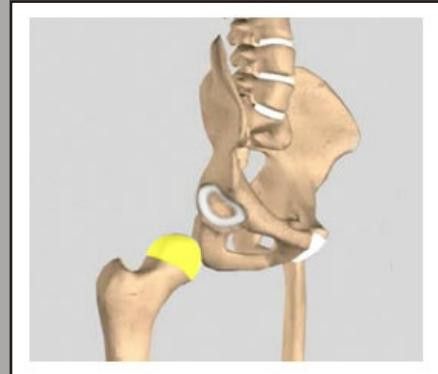(Fig. 6)

Unit 1:

Normal Hip Anatomy

Cartilage

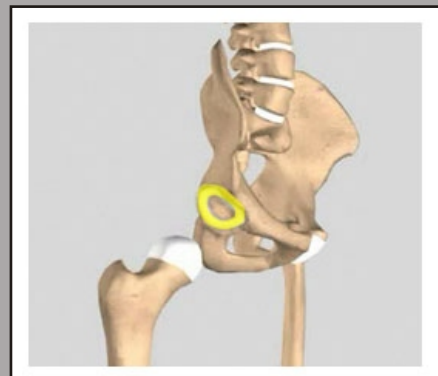(Refer fig. 7)



(Fig. 7)

Labrum

(Refer fig. 8)



(Fig. 8)

Pelvis

The pelvis is a large, flattened, irregularly shaped bone, constricted in the center and expanded above and below. It consists of three parts: the ilium, ischium, and pubis.

The socket, acetabulum, is situated on the outer surface of the bone and joins to the head of the femur to form the hip joint.

Femur

The femur is the longest bone in the skeleton. It joins to the pelvis, acetabulum, to form the hip joint. The upper part is composed of the Femoral head, Femoral neck, and Greater and Lesser trochanters.

What is FAI?

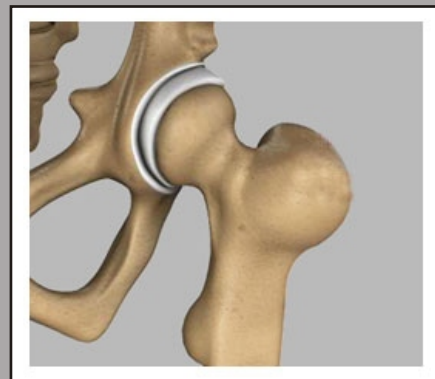
Femoroacetabular impingement (FAI) is a condition where there is too much friction in the hip joint from bony irregularities causing pain and decreased range of hip motion. The femoral head and acetabulum rub against each other creating damage and pain to the hip joint. The damage can occur to the articular cartilage (the smooth white surface of the ball or socket) or the labral tissue (the lining of the edge of the socket) during normal movement of the hip. The articular cartilage or labral tissue can fray or tear after repeated friction. Over time, more cartilage and labrum is lost until eventually the femur bone and acetabulum bone impact on one other. Bone on bone friction is commonly referred to as Osteoarthritis.

FAI impingement generally occurs as two forms: Cam and Pincer.

- Normal Hip
- Cam Impingement
- Pincer impingement
- Combination of cam and Pincer impingement

Normal Hip

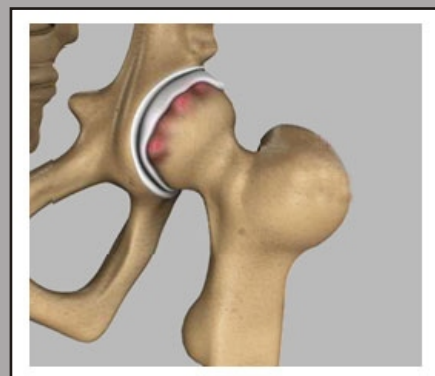
(Refer fig. 9)



(Fig. 9)

Cam Impingement

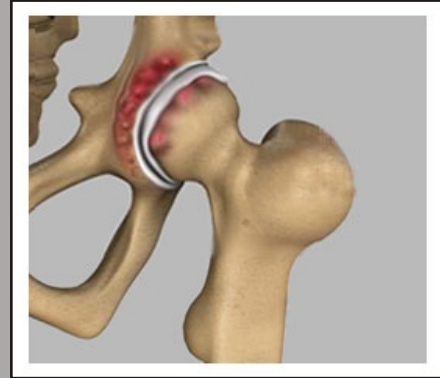
(Refer fig. 10)



(Fig. 10)

Combination of cam and Pincer impingement

(Refer fig. 11)



(Fig. 11)

CAM Impingement: The Cam form of impingement is when the femoral head and neck are not perfectly round, most commonly due to excess bone that has formed. This lack of roundness and excess bone causes abnormal contact between the surfaces.

PINCER Impingement: The Pincer form of impingement is when the socket or acetabulum rim has overgrown and is too deep. It covers too much of the femoral head resulting in the labral cartilage being pinched. The Pincer form of impingement may also be caused when the hip socket is abnormally angled backwards causing abnormal impact between the femoral head and the rim of the acetabulum.

Most diagnoses of FAI include a combination of the Cam and Pincer forms.

Symptoms of FAI

Symptoms of femoroacetabular impingement can include the following:

- Groin pain associated with hip activity
- Complaints of pain in the front, side or back of the hip
- Pain may be described as a dull ache or sharp pain
- Patients may complain of a locking, clicking, or catching sensation in the hip
- Pain often occurs to the inner hip or groin area after prolonged sitting or walking
- Difficulty walking uphill
- Restricted hip movement
- Low back pain
- Pain in the buttocks or outer thigh area

Risk Factors

A risk factor is something that is likely to increase a person's chance of developing a disease or condition. Risk factors for developing femoroacetabular impingement may include the following:

- Athletes such as football players, weight lifters, and hockey players
- Heavy laborers
- Repetitive hip flexion
- Congenital hip dislocation
- Anatomical abnormalities of the femoral head or angle of the hip
- Legg-Calves-Perthes disease: a form of arthritis in children where blood supply to bone is impaired causing bone breakdown.
- Trauma to the hip
- Inflammatory arthritis

Diagnosis

Hip conditions should be evaluated by an Orthopaedic hip surgeon for proper diagnosis and treatment.

- Medical History
- Physical Examination

Diagnostic Studies may include:

Xray

A form of electromagnetic radiation that is used to take pictures of bones. X-rays will show your surgeon the shape of the ball and socket as well as the amount of joint space present.

MRI

Magnetic and radio waves are used to create a computer image of soft tissue such as nerves and ligaments. An MRI assists your surgeon in ruling out other causes of hip pain. The MRI may be ordered with contrast dye to provide more information to your surgeon.

CT Scan

This test creates 3D images from multiple x-rays and shows your physician hip structures not seen on regular x-ray.

Conservative Treatment Options

Conservative treatment options refer to management of the problem without surgery. Non-surgical management of FAI will probably not change the underlying abnormal biomechanics of the hip causing the FAI but may offer pain relief and improved mobility.

Some conservative treatment measures include:

- Rest
- Activity Modification and Limitations
- Anti-inflammatory Medications
- Physical Therapy
- Injection of steroid and analgesic into the hip joint

Surgical Introduction

Hip Arthroscopy to repair femoroacetabular impingement is indicated when conservative treatment measures fail to provide relief to the patient. Hip Arthroscopy is a surgical procedure in which an arthroscope is inserted into the hip joint to assess and repair damage to the hip. Hip Arthroscopy is performed in a hospital operating room under general or regional anesthesia depending on you and your surgeon's preference. This surgery is usually performed as day surgery or outpatient surgery, enabling the patient to go home the same day.

The arthroscope used in Hip Arthroscopy is a small fiber-optic viewing instrument made up of a tiny lens, light source and video camera. The surgical instruments used in arthroscopic surgery are very small (only 3 or 4 mm in diameter), but appear much larger when viewed through an arthroscope.

The television camera attached to the arthroscope displays the image of the joint on a television screen, allowing the surgeon to look throughout the hip joint. The surgeon can then determine the amount or type of injury, and then repair or correct the problem as necessary.

In arthroscopic repair of FAI, your surgeon may perform the following procedures:

- **Chondroplasty:** This refers to surgery to repair torn cartilage or a torn labrum. Sutures are used to reattach the torn labrum or cartilage.
- **Microfracture:** This involves drilling holes into bare bone where cartilage is missing to promote the formation of new cartilage.
- **Labral/Cartilage debridement:** This type of debridement refers to cutting out and removing pieces of torn or frayed labrum or cartilage.
- **FAI decompression:** This involves removing any pressure areas, such as bony bumps, causing the impingement.
- **Osteoplasty:** This refers to a surgical procedure to modify or alter the shape of a bone.

In arthroscopic repair of FAI, your surgeon may perform the following procedures:

- Smaller incisions
- Minimal soft tissue trauma
- Less pain
- Faster healing time
- Lower infection rate
- Less scarring
- Earlier mobilization
- Usually performed as outpatient day surgery

Surgical Procedure For FAI

Your surgeon will make two or three small incisions, about 1/4 of an inch each, around the hip joint area. Each incision is called a portal. These incisions result in very small scars which in many cases are unnoticeable.

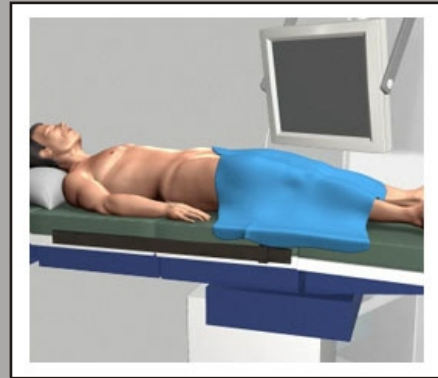
A blunt tube, called a Trocar, is inserted into each portal prior to the insertion of the arthroscope and surgical instruments.

In one portal, the arthroscope is inserted to view the hip joint. Along with the arthroscope, a sterile salt water (saline) solution is pumped into the joint to expand the viewing area, giving the surgeon a clear view and room to work.

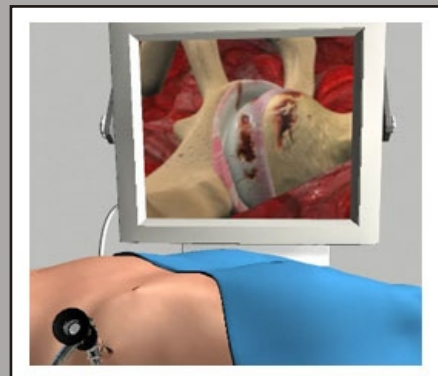
With the images from the arthroscope as a guide, the surgeon can look for any pathology or anomaly. The large image on the television screen allows the surgeon to see the joint directly and to determine the extent of the injuries and then to perform the particular surgical procedure as needed.

The other portals are used for the insertion of surgical instruments to probe various parts within the joint to determine the extent of the problem. If the surgeon sees an opportunity to treat a problem, a variety of surgical instruments can be inserted through this portal.

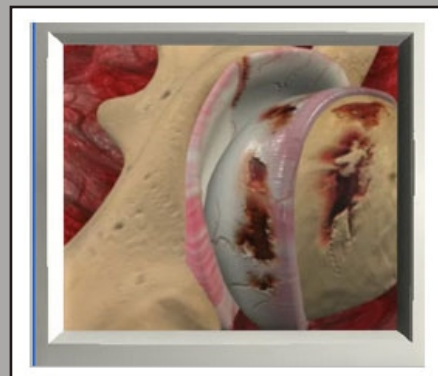
(Refer fig. 12 to 19)



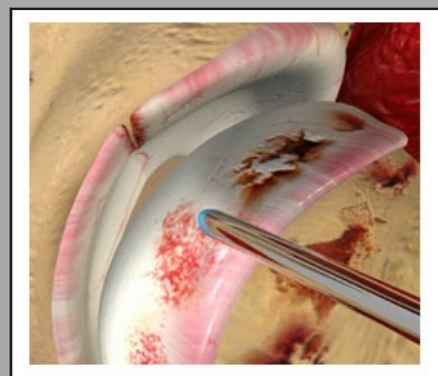
(Fig. 12)



(Fig. 13)



(Fig. 14)



(Fig. 15)

Unit 3:

Surgical Procedure

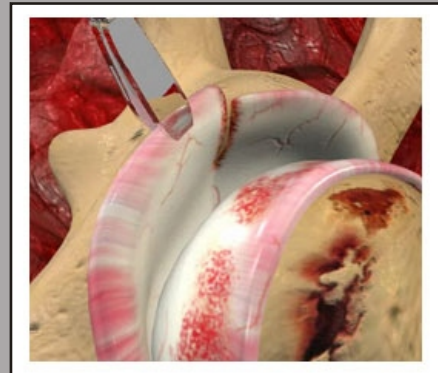
For FAI surgery, your surgeon will use a special instrument called a shaver to cut away or debride any frayed cartilage. If the labrum is torn, your surgeon will use sutures to preserve and reattach the labrum.

Any bony bumps present contributing to the impingement will also be shaved away and smoothed. Your surgeon may drill holes in bone that has no cartilage covering it. This technique is called microfracture and stimulates the formation of new cartilage.

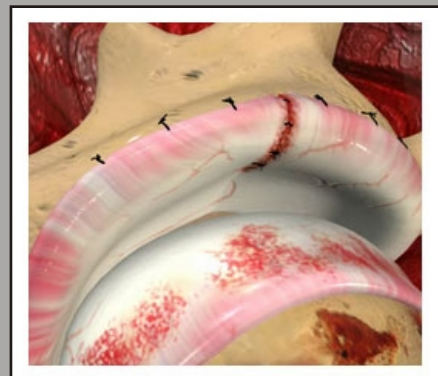Once your surgeon is satisfied with the results the instruments and arthroscope are removed from the portals.

The portals (incisions) are then closed by suturing or by tape.

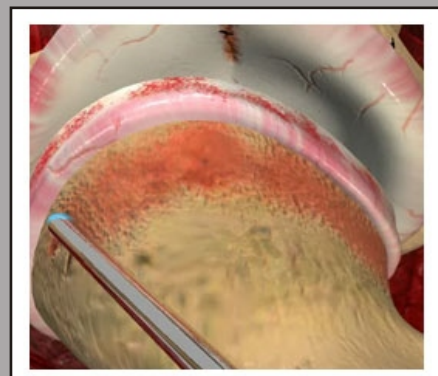
(Refer fig. 12 to 19)



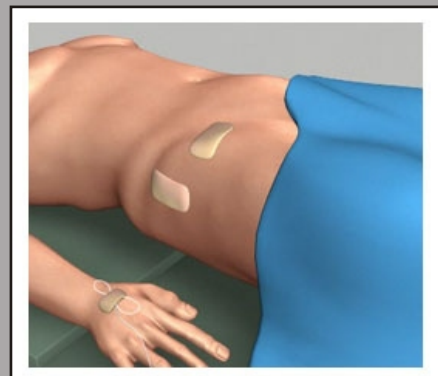
(Fig. 16)



(Fig. 17)



(Fig. 18)



(Fig. 19)

Post Operative Care

After surgery your surgeon will give you guidelines to follow depending on the type of repair performed and the surgeon's preference.

Common Post-operative guidelines include:

- Your surgeon will prescribe pain medications to keep you comfortable at home.
- Keep the incisions clean and dry. You may shower once the dressings are removed unless otherwise directed by your surgeon.
- You may have crutches for the first 2 weeks after surgery to limit weight bearing on the hip.
- You will be given specific instructions regarding activity and rehabilitation.
- Physical therapy will be ordered to restore normal hip function, flexibility and strength.
- It is important to keep all your post operative appointments with your surgeon to ensure a good outcome.
- Eating a healthy diet and not smoking will promote healing.

Risks and Complications

As with any major surgery there are potential risks involved. The decision to proceed with the surgery is made because the advantages of surgery outweigh the potential disadvantages. It is important that you are informed of these risks before the surgery takes place. Complications can be medical (general) or specific to Hip Arthroscopy surgery.

Medical complications include those of the anesthetic and your general well being. Almost any medical condition can occur so this list is not complete. Complications include:

- Allergic reactions to medications
- Blood loss requiring transfusion with its low risk of disease transmission
- Heart attacks, strokes, kidney failure, pneumonia, bladder infections
- Complications from nerve blocks such as infection or nerve damage
- Serious medical problems can lead to ongoing health concerns, prolonged hospitalization, or rarely death.

Complications are rare after hip arthroscopy surgery, but unexpected events can follow any operation. Your surgeon feels that you should be aware of complications that may take place so that your decision to proceed with this operation is taken with all relevant information available to you. Specific complications that can occur following hip arthroscopy include:

- Infection
- Nerve Damage
- Hemarthrosis
- Blood Clots
- Avascular Necrosis
- Failure to Relieve Pain

Infection

Infections can occur superficially at the portal insertion sites or in the joint space of the hip, a more serious infection.

Nerve Damage

Trauma to nerves may be temporary or permanent and can cause numbness, tingling, pain, and weakness. The nerves most at risk for damage include lateral femoral cutaneous from portal insertion and pudendal and sciatic nerve from traction.

Hemarthrosis

A condition caused by excess bleeding into the joint after the surgery is completed. This may require additional arthroscopic surgery to irrigate the joint and evacuate the blood.

Blood Clots

These can form in the calf muscles and can travel to the lung (Pulmonary embolism). These can occasionally be serious and even life threatening. If you get calf pain or shortness of breath at any stage, you should notify your surgeon.

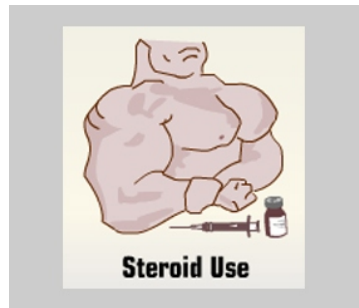
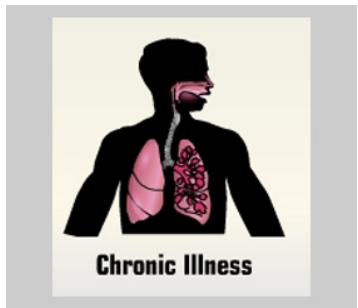Avascular Necrosis

AVN of the femoral head causes bone death due to lack of blood supply to the bone.

Failure to Relieve Pain

This is rare but may occur especially if some pain is coming from other areas such as the spine.

Risk factors that can negatively affect adequate healing after surgery include:



(Fig. 20)

Disclaimer

Although every effort is made to educate you on Femoroacetabular Impingement and take control, there will be specific information that will not be discussed. Talk to your doctor or health care provider about any concerns you have about FAI.

You must not proceed until you are confident that you understand this procedure, particularly, the complications.

YOUR SURGERY DATE

READ YOUR BOOK AND MATERIAL

VIEW YOUR VIDEO / CD / DVD / WEBSITE

PRE - HABILITATION

ARRANGE FOR BLOOD

MEDICAL CHECK UP

ADVANCE MEDICAL DIRECTIVE

PRE - ADMISSION TESTING

FAMILY SUPPORT REVIEW

Physician's Name : _____

Patient's Name : _____

Physician's Signature: _____

Patient's Signature: _____

Date : _____

Date : _____