



# Metal-on-Metal Total Hip Arthroplasty: Causes and High Incidence of Early Failure

DAVID FABI, MD; BRETT LEVINE, MD; WAYNE PAPROSKY, MD; CRAIG DELLAVALLE, MD; SCOTT SPORER, MD; GREGG KLEIN, MD; HARLAN LEVINE, MD; MARK HARTZBAND, MD

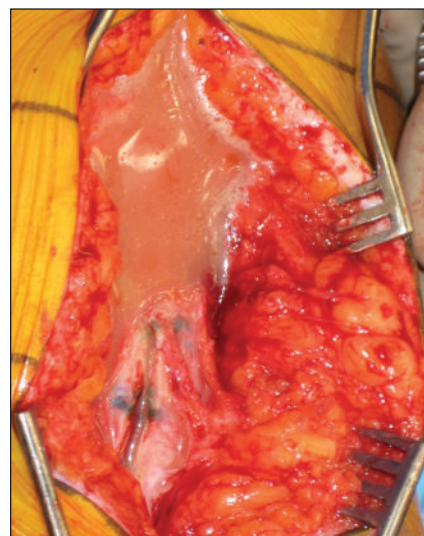
## abstract

Full article available online at [Healio.com/Orthopedics](http://Healio.com/Orthopedics). Search: 20120621-X

Early failures of metal-on-metal total hip arthroplasty (THA) occur due to aseptic loosening, metal hypersensitivity reactions, pseudotumor formation, and component seizing. The purpose of this study was to investigate the timing, common modes of failure, clinical outcomes, and incidence of metal-on-metal THA revisions.

A review was performed of 80 patients who underwent revision of a failed metal-on-metal THA for any reason. The most common reason for metal-on-metal failure was aseptic acetabular loosening, with a rate of 56.25% (45/80 patients). Early failure of metal-on-metal THAs was noted, with 78% of these revisions being performed within 2 years of the index operation and 92.5% within 3 years. Furthermore, 13% of patients experienced significant localized soft tissue reactions. Mean preoperative Harris Hip Score was  $42.35 \pm 14.24$  and mean postoperative Harris Hip Score was  $66.5 \pm 23.2$  (range, 9.55-95.4), with an average follow-up of  $438 \pm 492$  days (range, 40-2141), or 1.2 years.

It is imperative that clinicians be cognizant of the fact that the proposed advantages of metal-on-metal THA are not without potential detrimental sequelae. This article proposes an algorithm to aid in diagnosing the etiology for a painful metal-on-metal THA, as well as 2 classification schemes regarding metal-on-metal THA complications to help direct treatment.



**Figure:** Intraoperative photograph showing purulent-appearing material at revision for a failed metal-on-metal total hip arthroplasty. Cell count, frozen section, and intraoperative cultures were negative for infection.

*Dr Fabi is from San Diego Orthopaedic Associates Medical Group, San Diego, California; Drs Levine (Brett), Paprosky, and Della Valle are from Rush University Medical Center, Chicago, Illinois; and Drs Sporer, Klein, Levine (Harlan), and Hartzband are from Hartzband Center for Hip and Knee Replacements, Paramus, New Jersey.*

*Drs Fabi, Levine (Brett), Paprosky, Della Valle, Sporer, Klein, Levine (Harlan), and Hartzband have no relevant financial relationships to disclose.*

*Correspondence should be addressed to: David Fabi, MD, San Diego Orthopaedic Associates Medical Group, 4060 4th Ave, 7th Floor, San Diego, CA 92103 (dabilus@gmail.com).*

*doi: 10.3928/01477447-20120621-XX*



**M**etal-on-metal total hip arthroplasty (THA) is not a novel concept; these bearings were used frequently in the past. However, the use of metal-on-metal THA was essentially abandoned due to the high incidence of failure and the improved results seen with metal-on-polyethylene bearings.<sup>1</sup> The primary reason for the high failure of these early-generation metal-on-metal bearings was poor manufacturing methods and engineering.<sup>1</sup>

Recently, metal-on-metal bearings have experienced a clinical resurgence due to their proposed advantages, apparent improved metallurgy and fabrication, and a better understanding of the technical factors involved with the implantation of this articulation couple.<sup>2</sup> A major potential advantage of this bearing is that the use of larger femoral heads can minimize the risk of postoperative instability. Another advantage is that this bearing surface has demonstrated favorable wear rates compared with more traditional metal-on-polyethylene bearing surfaces, thus potentially leading to longer survival rates.<sup>2</sup>

Recently, several concerns with modern metal-on-metal THA designs have been elucidated. Numerous studies have demonstrated that patients with metal-on-metal bearings exhibit increased serum cobalt and chromium ion levels.<sup>3</sup> The long-term ramifications of this phenomenon are currently unknown due to the relatively recent release of these newer implants. Fortunately, a causative relationship between increased serum ion levels and malignancy or deleterious systemic effects has not been demonstrated thus far. However, multiple reports describe the localized effects and morbidity associated with metal sensitivity, metallosis, newly described pseudotumors, and aseptic lymphocytic vasculitis-associated lesions.<sup>4</sup> As a result, revisions of metal-on-metal bearing surfaces are being performed for reasons not well described in the current literature. Finally, another concern is company recalls of acetabular components with high early failure rates.

This study investigated metal-on-metal revisions performed at 2 high-volume revision total joint arthroplasty institutions, delineated the common causes and patient risk factors that may contribute to these failures, and assessed the postoperative clinical results of revision surgery for these failed metal-on-metal THAs. Radiographic evaluation of component placement, implant fixation, and osteolysis was reviewed to determine any other associations with risk for revision. To the authors' knowledge, only 1 other retrospective study investigates a large cohort of patients who have undergone revision of failed primary metal-on-metal THAs.<sup>5</sup>

## MATERIALS AND METHODS

A retrospective review was performed of 80 consecutive patients who underwent revision of a failed metal-on-metal THA for any reason at 2 high-volume revision total joint arthroplasty institutions. The revisions had taken place over the past 7 years, between February 2003 and October 2010. The surgeries were indicated and performed by a total of 7 surgeons [AQ 1]. Institutional Review Board approval was obtained at each hospital.

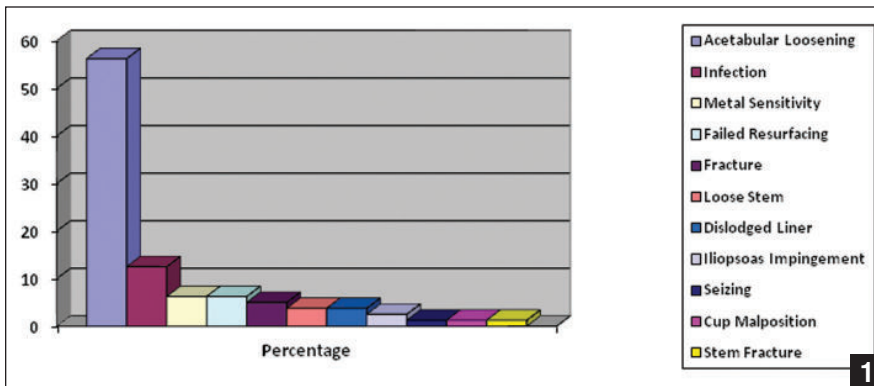
Inclusion criteria included consecutive men or women of any race who had undergone revision THA of a metal-on-metal THA for any reason. Exclusion criteria included patients who had undergone revision of a nonmetal-on-metal THA. Forty-one men and 39 women had an average age of  $57.9 \pm 10.7$  years (range, 31-84 years). Average patient height was 166.8 cm (range, 152.0-188.9 cm) and average weight was 88.5 kg (range, 58.9-163.3 kg), thus resulting in an average body mass index of 31.74 (range, 22.4-55.1).

A retrospective chart review of hospital and office medical records and appropriate radiographs was performed. Data points extracted for evaluation included causes of failure, patient demographics and comorbidities, time from initial surgery to revision, clinical outcome measures, and retrieved implant type. Histological

analysis, serum metal ion levels, and aspiration results at the time of surgery were recorded when available. Preoperative anteroposterior and lateral radiographs were reviewed in a blinded fashion to assess acetabular cup position, focusing on abduction and version, and to assess for signs of loosening and osteolysis. Associations between the diagnosis at the time of revision and component positioning were also evaluated.

A diagnosis of metal hypersensitivity/adverse metal reaction was made in the presence of elevated metal ion levels or local soft tissue reactions seen on histological evaluation after more common causes of failure had been ruled out. This workup often included erythrocyte sedimentation rate, C-reactive protein, hip aspirations, computed tomography scan, magnetic resonance imaging, or bone scans based on surgeon preference and indications. Preoperative erythrocyte sedimentation rate and C-reactive protein values were highly variable and often elevated in the cohort, with average values of 31.75 (range, 6-98) and 63.8 (range, 0.6-296.1), respectively. Normal erythrocyte sedimentation rate was less than 20 at the authors' institutions, and normal C-reactive protein value was less than 10.

Revisions were performed after the cause of failure had been determined and surgery was deemed appropriate to improve the functional status of the patient. All revisions were performed via a posterior approach, incorporating previous incisions when possible. The failed metal-on-metal articulations were revised to a metal-on-highly-crosslinked polyethylene or ceramic-on-highly-crosslinked polyethylene bearing. Standard deep venous thromboembolism prophylaxis measures were performed according to the preference of the operating surgeon. Similarly, weight-bearing status was dictated by the operating surgeon on a case-by-case basis. Outcomes of revision surgery were determined based on the Harris Hip Score (HHS).<sup>6</sup> Patients were seen postopera-



**Figure 1:** Graph showing causes of failure and demonstrating an overwhelming incidence of acetabular loosening.

tively on a routine basis based on the operating surgeon's customary follow-up protocol.

## RESULTS

The most common reason for metal-on-metal THA failure was aseptic acetabular loosening, with a rate of 56.25% (45/80 patients). Additional etiologies in descending order were infection (12.5%), metal hypersensitivity (6.25%), failed resurfacing (6.25%), fracture (5.0%), loose stem (3.75%), dislodged liner (3.75%), seizing (1.25%), cup malposition (1.25%), and femoral stem fracture (1.25%) (Figure 1).

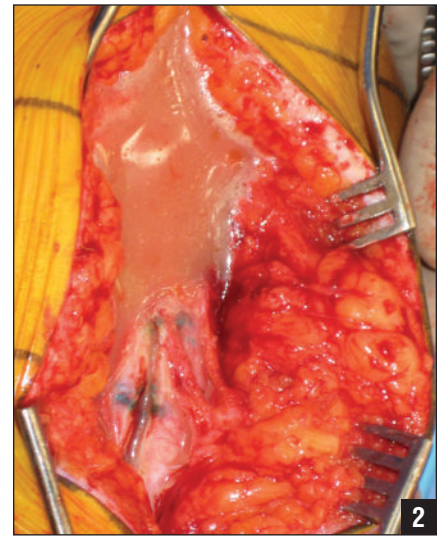
Analyzing acetabular loosening further, of the total of 45 cups that loosened, 35 (78%) were Durom acetabular cups (Zimmer, Warsaw, Indiana). The second most common cup that experienced aseptic loosening was the ASR cup (Depuy, Warsaw, Indiana), with a total of 4 (9%) cups that failed out of a total of 45. The remainder of the cups that loosened were 2 (4.4%) Magnum cups (Biomet, Warsaw, Indiana), 2 (4.4%) Pinnacle cups (Depuy), 1 (2.2%) Conserve cup (Wright Medical, Arlington, Tennessee), and 1 (2.2%) unknown cup.

When assessing the time to revision for aseptic acetabular loosening, failure occurred early and revision was performed at a mean of  $706 \pm 495$  days (range, 16-3072 days), or approximately 1.93 years, from the index operation.

Metal sensitivity as the primary diagnosis and cause of failure occurred in 5 (6.25%) of 80 patients. Four patients were women and 1 was a man. The histology at the time of revision surgery in these patients demonstrated partially necrotic soft tissue and predominance of lymphocytes, necrotic tissue, and extensive necrosis in 3 of the specimens, much like findings described in previous reports discussing metal hypersensitivity and adverse metal reactions.<sup>7</sup> The presence of necrotic tissue was not noted for the remainder of the specimens. Evaluation of the preoperative radiographs in 2 of these patients demonstrated a vertical and anteverted acetabular component in 1 patient and an overly anteverted component in the other. The preoperative radiographs of the remaining patients were unavailable for review.

Mean time from initial surgery to revision for metal sensitivity reactions was  $832 \pm 542$  days (range, 387-728 days), or approximately 2.28 years. It is important to note that metal sensitivity may also occur in conjunction with alternate causes of THA failure and represent a spectrum of local tissue reactions, ranging from minor inflammation and metallic staining to massive pseudotumors.


Failed resurfacings were seen in a total of 5 patients (3 women and 2 men). One woman aged 63 years and of unknown height and weight was revised for acetabular cup loosening. The second woman



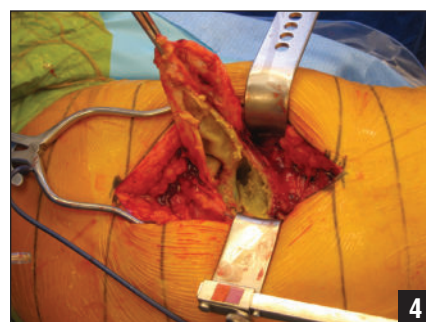
**Figure 2:** Intraoperative photograph showing purulent-appearing material at revision for a failed metal-on-metal total hip arthroplasty. Cell count, frozen section, and intraoperative cultures were negative for infection.

was aged 55 years with a height of 173 cm and weight of 163.3 kg, placing her in the super-morbidly obese category (body mass index, 54.6). Furthermore, her femoral component had been placed in a varus position and subsequently loosened. The third woman was aged 55 years and, on workup with magnetic resonance imaging, was found to have a large pseudotumor, and this was the reason for revision. The two men exhibited relatively small initial acetabular and femoral sizes, a proposed contributing factor to metal-on-metal failure.

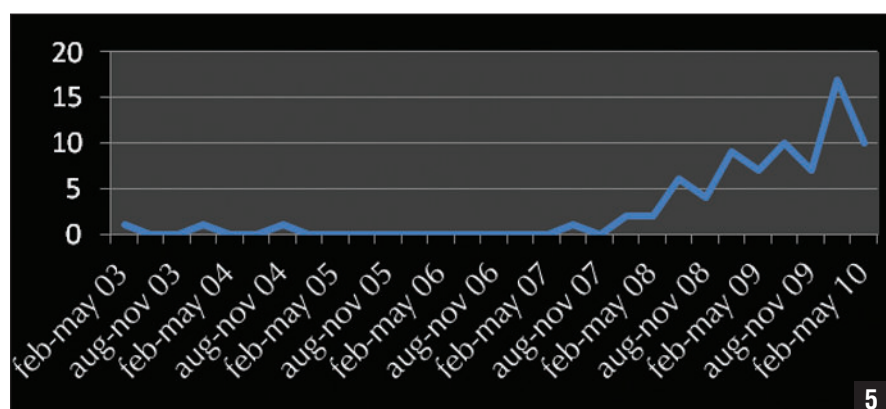
Ten 12.5% patients had significant metallosis or significantly involved local tissue changes due to the metal debris seen during revision surgery. In 4 of these patients, the intraoperative findings mimicked that of an infection with purulent-appearing material (Figure 2). However, in all of these patients, cell count, frozen section, and intraoperative cultures were negative. This clinical scenario is similar to case reports described in the literature.<sup>8</sup> With regard to functional results, likely secondary to the compromise in soft tissue function, relatively poor results were



**Figure 3:** Anteroposterior (A) and cross-table lateral (B) radiographs of a metal-on-metal total hip arthroplasty showing a retroverted acetabular component.



**Figure 4:** Intraoperative photograph of a pseudotumor found during revision total hip arthroplasty.



**Figure 5:** Graph showing the recent and increasing incidence of revision for failed metal-on-metal total hip arthroplasty at the authors' institutions.

seen. This was reflected in the comparison of mean pre- and postoperative HHS in these patients, which were  $44.9 \pm 11.5$  (range, 27.0-56.2) and  $67.5 \pm 26.6$  (range, 9.5-83.8), respectively. The acetabular cups in these situations were 4 ASR cups, 2 Pinnacle cups, 2 Magnum cups, 1 Birmingham Hip Resurfacing cup (Smith & Nephew, Memphis, Tennessee), and 1 unidentified cup. Four of these patients failed due to aseptic loosening. Inspection of component position when aseptic loosening was ruled out demonstrated vertical and anteverted components in 2 patients and vertical and retroverted components in 2 patients (Figure 3). The remaining 2 patients were revised for pseudotumor formation.

One patient with a pseudotumor had a Birmingham Hip Resurfacing cup and the other had an ASR cup. Both patients

were women; one aged 55 years and the other aged 72 years. Both patients exhibited elevated serum metal levels prior to revision surgery. They presented with masses, which, after workup consisting of an magnetic resonance imaging or computed tomography scan, were concluded to be pseudotumors and were removed at the time of revision (Figure 4).

Regarding overall clinical results for all reasons of metal-on-metal THA failure, mean preoperative HHS was  $42.35 \pm 14.24$  and mean postoperative HHS was  $66.5 \pm 23.2$  (range, 9.55-95.4), with an average follow-up of  $438 \pm 492$  days (range, 40-2141), or 1.2 years.

Early failure of metal-on-metal THAs for all reasons was noted, with 77.9% of these revisions being performed within 2 years of the index operation and 92.2% within 3 years. Furthermore, 90.9%

(70/77) of these revisions had been performed over a timespan of 2.3 years, between March 1, 2008, and June 23, 2010 (Figure 5).

## DISCUSSION

To the authors' knowledge, only 1 other study in the literature reported on metal-on-metal THA failures in a relatively large cohort of patients.<sup>5</sup> Browne et al<sup>5</sup> reported on a retrospective cohort of 37 patients who underwent revision for metal-on-metal THA failure. Their findings demonstrated that 10 of these patients experienced failure due to hypersensitivity reactions, 8 due to aseptic acetabular cup loosening, 2 due to iliopsoas impingement, 3 due to femoral neck fracture, and the remainder due to infection, instability, component malposition, and periprosthetic fracture.<sup>5</sup> The current study included a larger cohort with similar reasons of failure. The 3 most common reasons for revision were aseptic loosening, infection, and metal hypersensitivity reactions.

These causes of failure are related to the preponderance of cases using 2 cup designs that have been found to have a high rate of early revisions. The Durom cup is a nonmodular metal-on-metal acetabular component comprising a high carbon forged cobalt-chrome bearing surface and a titanium plasma spray surface. It is elliptical in shape, remaining 15° shy of being a full hemisphere.<sup>9</sup> Illgen et al,<sup>9</sup> in a case control study of 63 Durom cups, reported an 11.1% revision rate at 1 year.





Another study by Long et al<sup>10</sup> reported a 15% revision rate for loosening at a mean of 1.6 years. The Durom cup has been voluntarily withdrawn from the market. Similarly, the ASR and ASR XL acetabular implants have recently been recalled due to high early failure rates. Browne et al<sup>5</sup> reported failures of 2 Durom cups, 3 M2a cups (Biomet), 2 Conserve cups, and 1 Ultamet cup (Depuy). The current study's findings further demonstrate the need for a national registry to aid in early identification of component designs with a higher-than-anticipated failure rate.

Regarding other causes of metal-on-metal THA failure, the current study corroborates the findings of many previous studies. Proposed risk factors for metal-on-metal THA failure include female sex, implant design and size, acetabular component position, and obesity.<sup>11,12</sup> These risk factors were prevalent in the current study's cohort of patients.

In terms of metal sensitivity or adverse metal reactions as the primary diagnosis for failure, 4 of 5 patients in the current study who exhibited an adverse metal reaction were women, coinciding with observations in other studies.<sup>11-15</sup> This occurred in 6.5% of the current patient patients who underwent revision. Furthermore, localized soft tissue changes, whether in the setting of metal sensitivity alone or in concert with other failure reasons, were seen in 13% of patients, the majority of whom were women (7/10). The incidence of metal hypersensitivity is unclear in the literature, but current reports demonstrate and incidence of  $\leq 1\%$ .<sup>13</sup> In 5 current patients with metal sensitivity or adverse local tissue reactions as the primary diagnosis, time to revision for metal sensitivity or adverse metal reactions was approximately 2.28 years, similar to that seen in the study by Browne et al<sup>5</sup> and in other studies.<sup>11,12</sup>

The current study's results also support the idea that acetabular component position is a major factor in the development of an adverse metal reaction after metal-

on-metal THA.<sup>16,17</sup> Malposition of acetabular cups was observed in a considerable number of patients with adverse metal reactions or metal sensitivity in the current study's cohort. This supports the idea that if a surgeon chooses to perform metal-on-metal THA, he or she must ensure that abduction and anteversion are optimized to negate this potential technical risk factor.

Significant metallosis, soft tissue changes, and pseudotumors were observed in a number of patients at the time of revision. Histologic analysis often demonstrated significant tissue necrosis and lymphocytic infiltration. One would expect a compromise in soft tissue function with necrosis.<sup>7,11,12</sup> The function of the abductors and surrounding soft tissues is vital to the success of THA and the patient's clinical results. With these profound effects, postoperative function is significantly diminished, and this has been demonstrated in multiple reports, particularly with pseudotumor involvement.<sup>14,18</sup>

Overall, when including all reasons for failure, the current study's postoperative functional results demonstrated relatively low HHS scores, with a mean preoperative score of  $42.35 \pm 14.24$  and a mean postoperative score of  $66.5 \pm 23.2$  (range, 9.55-95.4) with an average follow-up of  $438 \pm 492$  days (range, 40-2141 days), or 1.2 years. These scores should be interpreted with caution because the causes for failure varied widely, and many patients have not yet reached 1-year follow-up. Thus, longer follow-up is needed to draw more definitive conclusions because these scores may yet increase. However, it is possible that revision for failed metal-on-metal THA has poorer results than revision for failed nonmetal-on-metal THAs, in part due to the deleterious localized effects on the soft tissues about the hip.

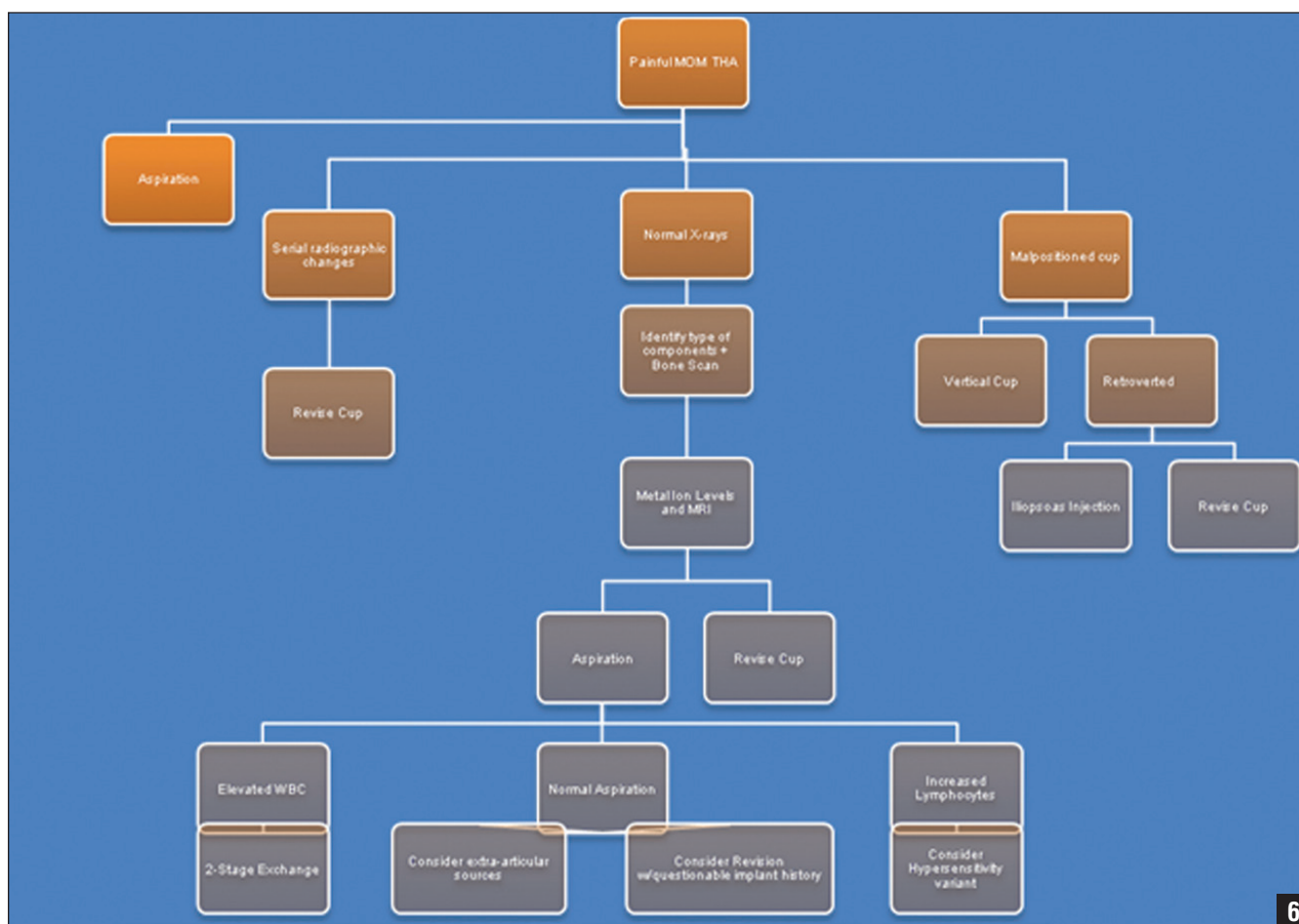
An important finding in this study was that when these bearing surfaces fail for reasons like acetabular loosening, metal sensitivity, or pseudotumor formation, they fail relatively early in the postopera-

tive period. The mean time to revision was approximately 1.93 years, although this covered a wide range of time. This would also support the idea that close follow-up of metal-on-metal THA patients is warranted.

Regarding elucidating a diagnosis for painful THA, the following algorithm is recommended (Figure 6). First, infection should be ruled out prior to revision THA for any reason via standard protocols (ie, sedimentation rate, C-reactive protein, hip aspiration, and cell count when appropriate). However, distinction between septic failure and metal-on-metal-related failures can at times be difficult to elucidate. As mentioned previously, metal-on-metal reactions can mimic infection in a variety of ways, with elevated inflammatory markers, elevated synovial cell counts, and effusions that grossly resemble purulent material (Figure 2).<sup>8</sup> In these instances, the surgeon must use his or her clinical judgment to differentiate both processes. Final intraoperative cultures and pathologic specimens (ie, looking for evidence of acute inflammation and number of white blood cells per high-power field) can help guide the surgeon in devising ultimate treatment protocols. If the diagnosis is still unclear, there should be a low threshold to initiate prolonged antibiotic therapy.

Infection issues aside, scrutiny of metal-on-metal THA radiographs is vital to assess acetabular cup position, identify components, and look for signs of loosening such as radiolucent lines or interval changes on serial films. When loosening is ruled out with stable serial radiographs or a negative bone scan, obtaining metal ion levels should be considered. Furthermore, if a soft tissue mass is present on examination, computed tomography or magnetic resonance imaging should be performed to detect a pseudotumor. In addition, if the patient has pain with resisted hip flexion, the diagnosis of iliopsoas impingement should be entertained. Component types, when necessary, should be identified by





**Figure 6:** Algorithm for the workup of a painful metal-on-metal total hip arthroplasty.

radiograph, previous operative report, or implant stickers. When an adverse metal reaction, metallosis, pseudotumor, and metal sensitivity is diagnosed, revision to a metal-on-polyethylene or ceramic-on-polyethylene articulation should be performed. The authors typically use a titanium sleeve over the femoral trunion in cases with significant morse taper corrosion.

The authors propose classification schemes for metal-on-metal THA complications and metal-on-metal THA local soft tissue reactions (Tables 1, 2). As with any useful classification, these were devised to also aid in devising and guiding treatment options.

When a patient presents with pain, a stable acetabular cup in good align-

ment, and elevated metal ion levels, only the bearing need be revised if the cup is modular and can receive a polyethylene liner. If the cup is monoblock, revision of the cup is likely necessary unless conversion to a dual-mobility device with modern day implants and cup retention can be performed. In a patient with pain, a malaligned component, and elevated metal ions, revision of the cup with a polyethylene liner should be considered. With a loose acetabular cup, the cup needs to be revised. With known problematic cups and patients with pain and elevated metal ions, revision of the cup is the treatment of choice. Finally, with a retroverted cup or with a large-profile metal-on-metal THA, iliopsoas impingement can occur. When this leads to significant pain, iliopsoas

release or revision of the acetabular cup should be performed.

Soft tissue complications can range from minimal to severe. These soft tissue effects can have serious implications on the ultimate functional status of the revision THA and thus the patient. Poor soft tissue function can lead to pain and a limp, and stability can be compromised. Ultimately, with abductor damage, stability is severely affected, and the use of constrained liner or other salvage options must be considered.

This study had limitations. It had the limitations inherent to the nature of a retrospective study. Furthermore, with multiple surgeons involved, follow-up protocols, work-up protocols, and treatments varied. Finally, follow-up was not long

Table 1

**Fabi-Levine Metal-on-Metal THA Failure Classification**

Type	Description	Treatment
1	Metal sensitivity: stable, well-aligned acetabular component, elevated metal ions, and pain	Revise bearing only to metal–poly or ceramic–poly if modular cup; if monoblock cup, revise cup with metal–poly or ceramic–poly bearing
2	Malpositioned cup: stable, malaligned acetabular component, elevated metal ions, and pain	Revise cup with metal–poly or ceramic–poly bearing
3	Loose cup	Revise cup with metal–poly or ceramic–poly bearing
4	Early failure cups: acetabular components with known high early failure rates	Revise cup with metal–poly or ceramic–poly bearing
5	Iliopsoas impingement: ion levels within normal limits, cup retroverted	Iliopsoas release or revise cup to optimal position with metal–poly or ceramic–poly bearing

Abbreviations: THA, total hip arthroplasty.

Table 2

**Fabi-Levine Metal-on-Metal THA Soft Tissue Complication Classification**


Type	Description	Treatment and Implications
I	Intracapsular effusion, capsule intact	Revise bearing and/or cup if needed, stability less of an issue
II	Extracapsular effusion, capsule affected, abductors intact	Revise bearing and/or cup if needed, stability more of an issue
III	Capsule affected, abductors affected	Revise bearing and/or cup if needed, stability severely compromised; consider constrained liner, other salvage options

Abbreviations: THA, total hip arthroplasty.

enough to make definitive conclusions pertaining to the clinical success of revision for failed metal-on-metal THAs.

## CONCLUSION

As more information is gathered on the performance of metal-on-metal THA, the orthopedic community will be better informed as to the best indications and contraindications for this bearing surface. With this valuable information, metal-on-metal THA performance can be optimized, thus taking advantage of the benefits of these bearing surfaces. Many studies have reported the satisfactory performance of these bearing surfaces when

ideal indication criteria are met.<sup>19–22</sup> The current study's findings underscore that we are still learning about the outcomes of these bearings and their potential unique complications. 

## REFERENCES

- MacDonald SJ. Metal-on-metal total hip arthroplasty: the concerns. *Clin Orthop Relat Res*. 2004; (429):86–93.
- Bozic KJ, Kurtz S, Lau E, et al. The epidemiology of bearing surface usage in total hip arthroplasty in the United States. *J Bone Joint Surg Am*. 2009; 91(7):1614–1620.
- Clarke IC, Good V, Williams P, et al. Ultra-low wear rates for rigid-on-rigid bearings in total hip replacements. *Proc Inst Mech Eng H*. 2000; 214(4):331–347.
- Clarke MT, Lee PT, Arora A, Villar RN. Levels of metal ions after small- and large-diameter metal-on-metal hip arthroplasty. *J Bone Joint Surg Br*. 2003; 85(6):913–917.
- Browne JA, Bechtold CD, Berry DJ, Hanssen AD, Lewallen DG. Failed metal-on-metal hip arthroplasties: a spectrum of clinical presentations and operative findings. *Clin Orthop Relat Res*. 2010; 468(9):2313–2320.
- Söderman P, Malchau H. Is the Harris hip score system useful to study the outcome of total hip replacement? *Clin Orthop Relat Res*. 2001; (384):189–197.
- Mahendra G, Pandit H, Kliskey K, Murray D, Gill HS, Athanasou N. Necrotic and inflammatory changes in metal-on-metal resurfacing hip arthroplasties. *Acta Orthop*. 2009; 80(6):653–659.
- Hsu AR, Kim JD, Fabi D, Levine BR. Adverse reactions in metal-on-metal total hip arthroplasty: two cases presenting as pseudo-septic acetabular component loosening. *Am J Orthop (Belle Mead NJ)*. 2011; 40(10):509–513.
- Illgen RL II, Heiner JP, Squire MW, Conrad DN. Large-head metal-on-metal total hip arthroplasty using the Durom acetabular component at minimum 1-year interval. *J Arthroplasty*. 2010; 25(6 suppl):26–30.
- Long WT, Dastane M, Harris MJ, Wan Z, Dorr LD. Failure of the Durom Metasul acetabular component. *Clin Orthop Relat Res*. 2010; 468(2):400–405.
- Langton DJ, Jameson SS, Joyce TJ, Hallab NJ, Natsu S, Nargol AV. Early failure of metal-on-metal bearings in hip resurfacing and large-diameter total hip replacement: a consequence of excess wear. *J Bone Joint Surg Br*. 2010; 92(1):38–46.
- Ollivier B, Darrah C, Barker T, Nolan J, Porteus MJ. Early clinical failure of the Birmingham metal-on-metal hip resurfacing is associated with metallosis and soft-tissue necrosis. *J Bone Joint Surg Br*. 2009; 91(8):1025–1030.
- Davies AP, Willert HG, Campbell PA, Learmonth ID, Case CP. An unusual lymphocytic perivascular infiltration in tissues around contemporary metal-on-metal joint replacements. *J Bone Joint Surg Am*. 2005; 87(1):18–27.
- Pandit H, Glyn-Jones S, McLardy-Smith P, et al. Pseudotumors associated with metal-on-metal hip resurfacings. *J Bone Joint Surg Br*. 2008; 90(7):847–851.
- Schmalzried TP, Tiberi JV. Metal-metal reactivity: houston, we have a problem! *Orthopedics*. 2010; 33(9):647. doi: 10.3928/01477447-20100722-45
- Grammatopoulos G, Pandit H, Glyn-Jones S, et al. Optimal acetabular orientation for hip resurfacing. *J Bone Joint Surg Br*. 2010; 92(8):1072–1078.



## ■ Feature Article

17. Onda K, Nagoya S, Kaya M, Yamashita T. Cup-neck impingement due to the malposition of the implant as a possible mechanism for metallosis in metal-on-metal total hip arthroplasty. *Orthopedics*. 2008; 31(4):396.
18. Grammatopoulos G, Pandit H, Kwon YM, et al. Hip resurfacings revised for inflammatory pseudotumor have a poor outcome. *J Bone Joint Surg Br*. 2009; 91(8):1019-1024.
19. Saito S, Ishii T, Mori S, Hosaka K, Ootaki M, Tokuhashi Y. Long-term results of metal-on-metal total hip arthroplasty. *Orthopedics*. 2010; 33(8). doi: 10.3928/01477447-20100625-11
20. Migaud H, Jobin A, Chantelot C, Giraud F, Laffargue P, Duquenois A. Cementless metal-on-metal hip arthroplasty in patients less than 50 years of age: comparison with a matched control group using ceramic-on-polyethylene after a minimum 5-year follow-up. *J Arthroplasty*. 2004; 19(8 suppl 3): 23-28.
21. Jacobs M, Gorab R, Mattingly D, Trick L, Southworth C. Three-to six-year results with the ultima metal-on-metal hip articulation for primary total hip arthroplasty. *J Arthroplasty*. 2004; 19(7 suppl 2):48-53.
22. Lombardi A, Mallory T, Cuckler J, Williams J, Berend K, Smith T. Mid-term results of a polyethylene-free metal-on-metal articulation. *J Arthroplasty*. 2004; 19(7 suppl 2):42-47.

**[AQ 1]** Are any of these surgeons also authors? If so, please provide their initials.